

Influence of Overnight Orthokeratology on Axial Elongation in Childhood Myopia

Tetsubiko Kakita,¹ Takabiro Hiraoka,² and Tetsuro Oshika¹

PURPOSE. This prospective study was conducted to assess the influence of overnight orthokeratology (OK) on axial elongation in children, with those wearing spectacles as controls.

METHODS. One hundred five subjects (210 eyes) were enrolled in the study. The OK group comprised 45 patients (90 eyes, age 12.1 ± 2.5 years, mean \pm SD; OK group) who matched the inclusion criteria for OK. The control group comprised 60 patients (120 eyes, 11.9 ± 2.0 years) who also matched the inclusion criteria for OK but preferred spectacles for myopia correction. Axial length was measured at baseline and after 2 years using ocular biometry, and the changes were evaluated and compared between the groups.

RESULTS. Ninety-two subjects (42 and 50 in the OK and control groups, respectively) completed the 2-year follow-up examinations. At baseline, the spherical equivalent refractive error was -2.55 ± 1.82 and -2.59 ± 1.66 D, and the axial length was 24.66 ± 1.11 and 24.79 ± 0.80 mm in the OK and control groups, respectively, with no significant differences between the groups. The increase in axial length during the 2-year study period was 0.39 ± 0.27 and 0.61 ± 0.24 mm, respectively, and the difference was significant ($P < 0.0001$, unpaired *t*-test).

CONCLUSIONS. OK suppressed axial elongation in myopic children, suggesting that this treatment can slow the progression of myopia to a certain extent. (*Invest Ophthalmol Vis Sci.* 2011;52:2170–2174) DOI:10.1167/iovs.10-5485

Myopia is one of the most common ocular abnormalities in humans. The prevalence of myopia is reported to be between 25% and 30% in the developed countries,^{1,2} with the incidence being higher among certain Asian populations (Lin LLK, et al. *IOVS* 1996;37:ARVO Abstract 4600). It is generally thought that progression of youth-onset myopia is attributable to axial elongation, which is not compensated for by reductions in the corneal and crystalline lens power.^{3–6}

Myopia can be corrected by spectacles or contact lenses. However, these treatments do not solve the problem of ocular axial elongation. It is well known that myopia is often associated with sight-threatening complications, such as retinal detachment, macular degeneration, and glaucoma.^{7–10} Furthermore, the risk of these complications increases with the severity of myopia and increased axial length.¹⁰ Arresting the progression of this myopic condition and preventing accentuated myopia would therefore contribute to the prevention of

these common ocular diseases and thus would likely have a very significant effect in reducing medical expenditures.

So far, the scientific community has been trying to find an effective means to slow or even arrest the development of myopia in children.¹¹ Several medical treatments have been tested, including topical application of tropicamide,¹² atropine,^{13–15} pirenzepine,^{16–18} and ocular hypotensive agents.^{19,20} However, there have been no ideal therapeutic modalities to effectively prevent myopic progression in light of efficacy, safety, economic feasibility, and ease of application.

One previous report has described the effectiveness of overnight orthokeratology (OK) for arresting the progression of myopia in the left eye of a 13-year-old boy, in whom it was found that axial elongation was less in the left eye than in the right after 2 years.²¹ This study showed the possibility that OK might be capable of suppressing ocular axial elongation in myopic children. Subsequently, Cho et al.²² conducted a 2-year pilot study to determine whether OK could ameliorate the progression of myopia in children. The authors compared the growth of axial length in 35 children undergoing OK with that of 35 children wearing single-vision spectacles and reported that the increases in axial length were significantly smaller in the OK group than in the spectacles group. In that study, however, the data for the control group were obtained at other facilities, where axial length was measured using different devices.²³ Therefore, the study was not considered to have been adequately controlled. More recently, similar results have been confirmed by Walline et al.²⁴ However, theirs was also a nonrandomized study with an inappropriate control group that had been recruited from a different study.²⁵ In addition, axial length measurements were performed with a conventional contact type A-scan ultrasound device. In recent years, it has been shown that a laser interferometer (IOLMaster; Carl Zeiss Meditec, Dublin, CA) yields highly reproducible, precise, non-contact, and rapid axial length measurements with less burden on the patient.²⁶ Such features of the interferometer are considerably advantageous for repeated, longitudinal measurements of axial length in children.

We conducted the current prospective study using interferometry to find out how the continued use of OK affects axial growth in children. Children wearing spectacles and attending the same clinic were recruited as controls.

METHODS

The survey was conducted between November 2002 and June 2007. Forty-five patients who matched the inclusion criteria (Table 1) were enrolled in the OK group. There were 22 boys and 23 girls, ranging in age from 8 to 16 (12.1 ± 2.5 [mean \pm SD]) years. One hundred twenty eyes of 60 individuals served as controls. They also matched the inclusion criteria for OK but preferred spectacles to OK for the correction of myopia. The control group included 28 boys and 32 girls, ranging in age from 8 to 16 (11.9 ± 2.0) years.

The study was conducted in accordance with the tenets of the Declaration of Helsinki and approved by the Ethics Committee of

From the ¹Kakita Eye Clinic, Chiba, Japan; and the ²Department of Ophthalmology, Institute of Clinical Medicine, University of Tsukuba, Ibaraki, Japan.

Submitted for publication March 6, 2010; revised May 19, July 2, September 16, and October 3 and 14, 2010; accepted October 27, 2010.

Disclosure: T. Kakita, None; T. Hiraoka, None; T. Oshika, None
Corresponding author: Tetsuhiko Kakita, Kakita Eye Clinic, 4-1-15, Minaminagareyama, Nagareyama, Chiba, 270-0163, Japan; kec@kakitaeyeclinic.com.

TABLE 1. Inclusion Criteria

Ages from 8 to 16 years at baseline
No history of OK or the use of contact lenses
Noncycloplegic autorefracton (spherical equivalent) from -10.00 to -0.50 D in both eyes
Astigmatism (noncycloplegic autorefracton) ≤ 1.50 D in both eyes
Anisometropia (noncycloplegic autorefracton) ≤ 1.50 D
Best corrected visual acuity ≥ 0.00 logMAR units in both eyes (Snellen equivalent to 20/20)
No strabismus by a cover-uncover test either with or without refractive correction
Birth weight equal to or more than 1250 g
No known ocular, systemic or neurodevelopmental deviations that might affect refractive development
No use of medications that might affect refractive development

Kakita Eye Clinic. Informed consent was obtained in writing from all participants and their guardians after an explanation of the nature and possible consequences of the study.

The OK lenses used in this study were four-zone, reverse-geometry lenses (Emerald Lenses; Euclid Systems Corp., Herndon, VA, manufactured from Boston XO material; Polymer Technology Corp., Wilmington, MA) with a nominal Dk of 100×10^{-11} cm²/s(mL O₂/mL · mm Hg). The nominal central thickness of the lenses was 0.22 mm and the diameter was 10.6 mm. The patients were fitted with the lenses according to the manufacturer's specifications. After the lenses had been dispensed, the patients were advised to wear their OK lenses every night for at least 7 consecutive hours.

The patients in the control group wore single-vision glasses, which were prescribed by a certified ophthalmic technician and modified according to any refractive changes during the follow-up period.

The OK group returned for examination every 3 months and underwent slit lamp examinations for any adverse events. The OK lens fit was evaluated at these visits. The control group returned for examination every 6 months. OK lenses and spectacles were replaced if visual acuity was found to change by more than 0.30 logMAR units during the follow-up.

It has been reported that corneal thinning stabilizes by the end of the week after OK,²⁷ or that thinning continues for 1 or 2 months.^{28,29} In the present study, therefore, axial length was measured 3 months after the start of OK, which was used as the baseline data for axial length. As for refraction and visual acuity, data obtained before starting OK were used as the baseline values. In the control group, axial length, refraction, and visual acuity were measured when the subject started wearing spectacles. In both groups, OK or spectacles were continued for 2 years, and axial length, refraction, and visual acuity were measured at the end of the 2-year study period (i.e., 2 years and 3 months for the OK group).

The axial length was evaluated using a noncontact optic biometric device (IOLMaster; Carl Zeiss Meditec), between 3 and 6 o'clock in the

afternoon. On each occasion, five successive measurements were taken, and their mean was used as a representative value. The measurements were performed by a single examiner who was blinded to the original refractive status and subjects' assignment to either group.

The changes in axial length were evaluated prospectively and compared. In each group, a paired *t*-test was used to compare axial length at baseline and at 2 years after treatment. An unpaired *t*-test was used to compare the changes in axial length between groups.

RESULTS

Among the 45 patients who were enrolled initially in the OK group, 42 patients (male 21, female 21) successfully completed the 2-year follow-up examinations. Their ages ranged from 8 to 16 years (12.0 ± 2.6). Thirteen (31%) patients were 8 to 10 years of age, 23 (55%) were 11 to 13 years, and 6 (14%) were 14 to 16 years. At baseline, their spherical equivalent refractive error ranged from -0.50 to -10.00 (mean, -2.55 ± 1.82) D; logMAR uncorrected visual acuity was between 0.30 and 1.40 (mean, 0.80 ± 0.32), and axial length ranged from 21.98 to 27.67 mm (mean, 24.66 ± 1.11 ; Table 2). Three patients in the OK group withdrew from the study because of insufficient improvement in uncorrected visual acuity (two patients) and loss to follow-up.

Among the 60 patients in the spectacle control group, 50 (22 boys, 28 girls) successfully completed the 2-year follow-up examinations. Their ages ranged from 8 to 16 (11.9 ± 2.1) years. Seventeen (34%) were 8 to 10 years of age, 26 (52%) were 11 to 13 years, and 7 (14%) were 14 to 16 years. At baseline, their spherical equivalent refractive errors were between -0.50 and -9.00 (-2.59 ± 1.66) D; logMAR uncorrected visual acuity ranged from 0.10 to 1.40 (0.83 ± 0.31), and axial length ranged from 22.53 to 28.00 mm (24.79 ± 0.80) (Table 2). Ten patients in the control group missed follow-up examinations and withdrew from the study.

At baseline, the two groups were comparable in terms of spherical equivalent refractive error, uncorrected visual acuity, axial length, age (unpaired *t*-test), and distribution of the sexes (Mann-Whitney U test; Table 2). There were also no significant differences in age distribution (8–10, 11–13, and 14–16 years) between the groups. In the OK group, spherical equivalent refractive error decreased significantly from -2.55 ± 1.82 D at baseline to -0.68 ± 1.02 D at 2 years after the treatment ($P < 0.0001$, paired *t*-test). In the control group, refractive error increased significantly from -2.59 ± 1.66 to -3.83 ± 1.76 D ($P < 0.0001$).

In 2 years, axial length increased from 24.66 ± 1.11 to 25.05 ± 1.06 mm in the OK group and from 24.79 ± 0.80 to 25.40 ± 0.84 mm in the spectacle control group. In both groups, significant axial elongation was recognized during 2 years ($P < 0.0001$). The increases in axial length were

TABLE 2. Baseline Data of Patients who Completed 2-year Follow-up Examinations in the OK and Control Groups

	OK (mean \pm SD)	Control (mean \pm SD)	<i>P</i>
Age, y	12.0 ± 2.6	11.9 ± 2.1	$P = 0.6129^*$
Sex, M/F	21/21	22/28	$P = 0.4378^\dagger$
Spherical equivalent refractive error, D	-2.55 ± 1.82	-2.59 ± 1.66	$P = 0.8771^*$
Uncorrected visual acuity, logMAR	0.80 ± 0.32	0.83 ± 0.31	$P = 0.5064^*$
Axial length, mm	24.66 ± 1.11	24.79 ± 0.80	$P = 0.3434^*$

No significant intergroup differences or variations in distribution patterns at baseline in spherical equivalent refractive error, uncorrected visual acuity, axial length, age, or sex.

* Unpaired *t*-test.

† Mann-Whitney U test.

0.39 ± 0.27 and 0.61 ± 0.24 mm in the OK and spectacle groups, respectively, and the increase in the OK group was significantly smaller than that in the spectacle group (unpaired *t*-test, $P < 0.0001$).

Increases in axial length were analyzed in relation to the spherical equivalent refractive error at baseline. A significant correlation was found between these parameters in the OK group (Pearson's correlation coefficient; $r = 0.290$, $P = 0.0076$), but not in the control group ($r = 0.038$, $P = 0.7090$; Figs. 1, 2).

In the OK group, two patients had mild corneal erosion, which improved after 1 week of treatment cessation, and subsequent OK treatment was resumed without any sequelae. No other complications, such as corneal ulcer, were noted. There were no adverse events in the spectacle group.

DISCUSSION

In 2005, Cho et al.²² reported that axial length in children increased over a 2-year period by 0.29 ± 0.27 mm in an OK-treated group and by 0.54 ± 0.27 mm in a control group treated with spectacles. In 2009, Walline et al.²⁴ reported similar findings; the mean increase in axial length in 2 years was 0.25 mm in the OK group and 0.57 mm in the control group. Although similar results were obtained in our study, our subjects showed slightly a greater increase in axial length in 2 years: 0.39 ± 0.27 mm in the OK group versus 0.61 ± 0.24 mm in the control group.

There were several limitations to the study conducted by Cho et al.²² First, they used a contact-type ultrasonic A-mode device to measure axial length. It is difficult to measure axial length precisely with proper fixation and no indentation in children between 7 and 12 years. Second, the data of the control spectacles-wearing group were taken from another study conducted by Edwards et al.,²³ in which a different ultrasonic device was used to measure axial length. Different examiners conducted the measurements in a nonmasked way. Third, axial length at the start of OK was used as the baseline data. It has been reported that the central corneal thinning caused by OK ranges from -12 to -19 μm over a span of 3 months.^{27,29,30} This thinning is thought to be epithelial in origin, whereas stromal change is negligible.³⁰ Furthermore, OK does not alter the posterior corneal curvature or the anterior chamber depth.³¹ Thus, corneal thinning due to OK is

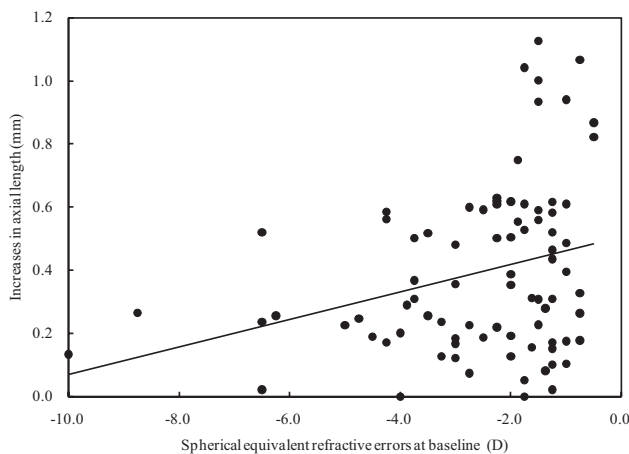


FIGURE 1. Increases in axial length and spherical equivalent refractive errors at baseline in the OK group. A significant correlation was found between the increases in axial length and spherical equivalent refractive errors at the baseline (Pearson's correlation coefficient, $r = 0.290$; $P = 0.0076$).

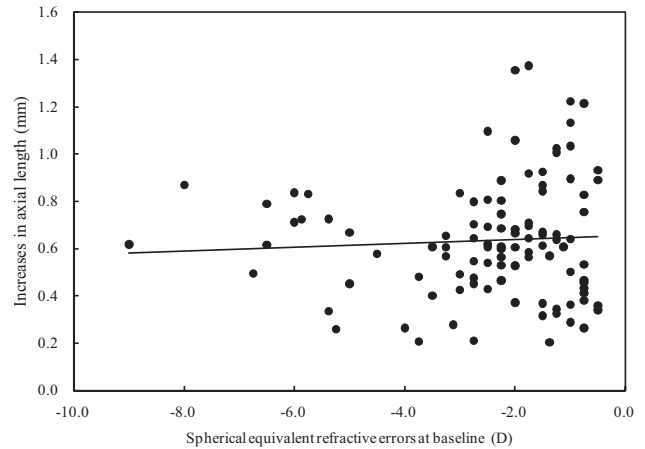


FIGURE 2. Increases in axial length and spherical equivalent refractive errors at baseline in the spectacle group. No significant correlation was observed between the increases in axial length and spherical equivalent refractive errors at the baseline (Pearson's correlation coefficient, $r = 0.038$; $P = 0.7090$).

attributable to epithelial changes, which can confound the study results. The study by Walline et al.²⁴ also had similar weaknesses.

In the present study, laser interferometry (IOLMaster; Carl Zeiss Meditec) was used to conduct noncontact measurements of axial length. This device is very suitable for axial length measurements in children, thanks to its high reproducibility, precision, lack of direct contact, and rapidity.²⁶ Moreover, both the OK and spectacle groups in our study were examined at a single center, by a single examiner, using a single instrument. Because the axial length taken 3 months after the start of OK was used as the baseline data, any initial corneal flattening by OK was excluded from the analysis of changes in axial length. Our improved study design allowed us to demonstrate that OK significantly slowed the axial elongation in myopic children.

Little is known about how OK retards axial elongation in childhood myopia. It has been postulated that growth of the eye is modulated by a visual feedback response to the defocus produced by the eye's refractive state.^{32,33} Recently, some experimental studies of primates have yielded data to support the concept that the peripheral retina is able to influence ocular growth and refractive development.³⁴⁻³⁷ Similarly in humans, it is known that the peripheral retina can influence refractive development (e.g., retinal diseases that affect mainly the peripheral retina)^{38,39} and that peripheral laser photocoagulation for retinopathy of prematurity^{40,41} is often associated with significant refractive errors. Mutti et al.^{42,43} reported that myopic children have greater relative hyperopia in the periphery with respect to axial refraction, indicating a prolate ocular shape (an axial length exceeding the equatorial diameter), compared with relative peripheral myopia and an oblate shape (an equatorial diameter exceeding the axial length) for emmetropes and hyperopes, suggesting that hyperopic defocus in the periphery promotes axial myopia in humans. Treatment strategies and methods for correcting not only central refractive error but also peripheral defocus and image quality may be effective to control eye growth in myopic children.^{34,44} From this viewpoint, OK seems to be a promising method, inducing a reduction in central epithelial thickness and an increase in the more peripheral annular zone to yield a flatter central area.^{29,45} Although these corneal changes eliminate myopic refractive error in the central area, there is probably an increase in myopia in intermediate peripheral areas caused by

the annular ridge of epithelial and stromal thickening.⁴⁶ Therefore, light passing through the flattened central area of the cornea forms an image on the fovea, while light passing through the midperipheral cornea, which became steeper than the original shape after OK, focuses at a point closer to the retina at the periphery. In other words, this type of corneal morphology can eliminate or decrease relative peripheral hyperopia that is often associated with myopic eyes.⁴⁷ At this stage, however, this hypothesis remains speculative and should be tested in a detailed evaluation of ocular shape and peripheral refractive status, before and after the start of OK, in addition to the parameters we examined in the present study. In addition, it may be useful to examine the relationship between peripheral aberrations and axial elongation, because substantial increases in higher-order aberrations after OK were observed also in the peripheral field of the eye.⁴⁷

There was a significant relationship between the increases in axial length and baseline refractive errors in the OK group, whereas this relationship was not significant in the control group. When compared between the two scatterplots (Figs. 1, 2), the distributions of axial growth were similar in both groups for low baseline myopes, showing a wide variety of increases in axial length. However, the distributions were different in high baseline myopes. The increases in axial length were much smaller in the OK group than in the spectacle group, indicating that when the baseline myopia is more severe, the axial elongation after OK is less marked. Generally, the cornea becomes more oblate (with a flat central area and increasing power toward the periphery) when more severe myopia is corrected by OK lenses with a very flat base curve. This probably leads to a greater decrease of hyperopic defocus at the periphery, thus exerting a greater suppressive effect on axial growth.

Although almost all subjects were adequately treated by OK, the myopic refractive error of only one subject (12-year-old boy) was not sufficiently corrected over the 2-year study period. The original refractive error of this case was -10.0 and -8.75 D in the right and left eyes, respectively, and these myopic refractive errors were the largest in the OK group. The 2-year treatment of OK improved these refractive errors from -10.0 to -4.0 D and from -8.75 to -2.0 D in the right and left eyes, respectively. LogMAR uncorrected visual acuity was also improved from 1.398 to 0.523 in the right eye and from 1.222 to 0.155 in the left eye. Despite the fact that his refractive error after the treatment was not emmetropic and his visual acuity did not reach 20/20 (0.00 logMAR) in both eyes, he was satisfied with his visual outcomes and was able to perform his daily activities without additional spectacle corrections. In this case, the increase in axial length during the 2-year study period was 0.13 and 0.27 mm in the right and left eyes, respectively, showing much smaller axial elongation in comparison to that in the spectacle group. This fact may support the concept that improvement in peripheral refractive status itself exerts a suppressive effect on axial growth even if the central refraction is not fully corrected. However, the peripheral refractive status of this subject is unknown. Further studies are needed to investigate whether elimination or reduction in hyperopic defocus in the periphery without enough correction in the central retina can retard axial elongation in childhood myopia.

In conclusion, our study has demonstrated a significant axial elongation in two groups of children treated with OK and with spectacles over a 2-year period. However, the axial elongation in the OK group was significantly smaller than that in the controls. The mean axial growth rate was 0.15 mm per year in the OK group and 0.30 mm per year in the spectacle control group: a very marked difference. Although OK cannot completely arrest axial elongation in myopic children, it can retard it to a certain extent, suggesting the potential of this treatment for slowing the progression of myopia.

References

1. Sperduto RD, Seigel D, Roberts J, Rowland M. Prevalence of myopia in the United States. *Arch Ophthalmol*. 1983;101:405-407.
2. Fledelius HC. Is myopia getting more frequent?—a cross-sectional study of 1416 Danes aged 16 years+. *Acta Ophthalmol (Copenh)*. 1983;61:545-559.
3. Tokoro T, Suzuki K. Changes in ocular refractive components and development of myopia during seven years. *Jpn J Ophthalmol*. 1969;13:27-34.
4. Fledelius HC. Ophthalmic changes from age of 10 to 18 years: a longitudinal study of sequels to low birth weight. III. Ultrasound ophthalmometry and keratometry of anterior eye segment. *Acta Ophthalmol (Copenh)*. 1982;60:393-402.
5. Fledelius HC. Ophthalmic changes from age of 10 to 18 years: a longitudinal study of sequels to low birth weight. IV. Ultrasound ophthalmometry of vitreous and axial length. *Acta Ophthalmol (Copenh)*. 1982;60:403-411.
6. Hosaka A. The growth of the eye and its components: Japanese studies. *Acta Ophthalmol Suppl*. 1988;185:65-68.
7. Goldschmidt E. Ocular morbidity in myopia. *Acta Ophthalmol Suppl*. 1988;185:86-87.
8. The Eye Disease Case-Control Study Group. Risk factors for idiopathic rhegmatogenous retinal detachment. *Am J Epidemiol*. 1993;137:749-757.
9. Mitchell P, Hourihan F, Sandbach J, Wang JJ. The relationship between glaucoma and myopia: the Blue Mountains Eye Study. *Ophthalmology*. 1999;106:2010-2015.
10. Saw SM, Gazzard G, Shih-Yen EC, Chua WH. Myopia and associated pathological complications. *Ophthalmic Physiol Opt*. 2005;25:381-391.
11. Saw SM, Gazzard G, Au Eong KG, Tan DT. Myopia: attempts to arrest progression. *Br J Ophthalmol*. 2002;86:1306-1311.
12. Schwartz JT. Results of a monozygotic cotwin control study on a treatment for myopia. *Prog Clin Biol Res*. 1981;69:249-258.
13. Yen MY, Liu JH, Kao SC, Shiao CH. Comparison of the effect of atropine and cyclopentolate on myopia. *Ann Ophthalmol*. 1989;21:180-182; 187.
14. Shih YF, Chen CH, Chou AC, Ho TC, Lin LL, Hung PT. Effects of different concentrations of atropine on controlling myopia in myopic children. *J Ocul Pharmacol Ther*. 1999;15:85-90.
15. Lee JJ, Fang PC, Yang IH, et al. Prevention of myopia progression with 0.05% atropine solution. *J Ocul Pharmacol Ther*. 2006;22:41-46.
16. Siatkowski RM, Cotter S, Miller JM, et al. Safety and efficacy of 2% pirenzepine ophthalmic gel in children with myopia: a 1-year, multicenter, double-masked, placebo-controlled parallel study. *Arch Ophthalmol*. 2004;122:1667-1674.
17. Tan DT, Lam DS, Chua WH, Shu-Ping DF, Crockett RS; Asian Pirenzepine Study Group. One-year multicenter, double-masked, placebo-controlled, parallel safety and efficacy study of 2% pirenzepine ophthalmic gel in children with myopia. *Ophthalmology*. 2005;112:84-91.
18. Siatkowski RM, Cotter SA, Crockett RS, et al. Two-year multicenter, randomized, double-masked, placebo-controlled, parallel safety and efficacy study of 2% pirenzepine ophthalmic gel in children with myopia. *J AAPOS*. 2008;12:332-339.
19. Jensen H. Timolol maleate in the control of myopia: a preliminary report. *Acta Ophthalmol Suppl*. 1988;185:128-129.
20. Wiener M. The use of epinephrine in progressive myopia. *Am J Ophthalmol*. 1931;14:520-522.
21. Cheung SW, Cho P, Fan D. Asymmetrical increase in axial length in the two eyes of a monocular orthokeratology patient. *Optom Vis Sci*. 2004;81:653-656.
22. Cho P, Cheung SW, Edwards M. The longitudinal orthokeratology research in children (LORIC) in Hong Kong: a pilot study on refractive changes and myopic control. *Curr Eye Res*. 2005;30:71-80.
23. Edwards MH, Li RW, Lam CS, Lew JK, Yu BS. The Hong Kong progressive lens myopia control study: study design and main findings. *Invest Ophthalmol Vis Sci*. 2002;43:2852-2858.
24. Walline JJ, Jones LA, Sinnott LT. Corneal reshaping and myopia progression. *Br J Ophthalmol*. 2009;93:1181-1185.

25. Walline JJ, Jones LA, Mutti DO, Zadnik K. A randomized trial of the effects of rigid contact lenses on myopia progression. *Arch Ophthalmol*. 2004;122:1760-1766.
26. Chan B, Cho P, Cheung SW. Repeatability and agreement of two A-scan ultrasonic biometers and IOLMaster in non-orthokeratology subjects and post-orthokeratology children. *Clin Exp Optom*. 2006;89:160-168.
27. Soni PS, Nguyen TT, Bonanno JA. Overnight orthokeratology: visual and corneal changes. *Eye Contact Lens*. 2003;29:137-145.
28. Soni PS, Nguyen TT, Bonanno JA. Overnight orthokeratology: refractive and corneal recovery after discontinuation of reverse-geometry lenses. *Eye Contact Lens*. 2004;30:254-262.
29. Nichols JJ, Marsich MM, Nguyen M, Barr JT, Bullimore MA. Overnight orthokeratology. *Optom Vis Sci*. 2000;77:252-259.
30. Alharbi A, Swarbrick HA. The effects of overnight orthokeratology lens wear on corneal thickness. *Invest Ophthalmol Vis Sci*. 2003;44:2518-2523.
31. Tsukiyama J, Miyamoto Y, Higaki S, et al. Changes in the anterior and posterior radii of the corneal curvature and anterior chamber depth by orthokeratology. *Eye Contact Lens*. 2008;34:17-20.
32. Norton TT, Siegwart JT Jr. Animal models of emmetropization: matching axial length to the focal plane. *J Am Optom Assoc*. 1995;66:405-414.
33. Flitcroft DI. A model of the contribution of oculomotor and optical factors to emmetropization and myopia. *Vision Res*. 1998;38:2869-2879.
34. Smith EL 3rd, Kee CS, Ramamirtham R, Qiao-Grider Y, Hung LF. Peripheral vision can influence eye growth and refractive development in infant monkeys. *Invest Ophthalmol Vis Sci*. 2005;46:3965-3972.
35. Smith EL 3rd, Ramamirtham R, Qiao-Grider Y, et al. Effects of foveal ablation on emmetropization and form-deprivation myopia. *Invest Ophthalmol Vis Sci*. 2007;48:3914-3922.
36. Huang J, Hung LF, Ramamirtham R, et al. Effects of form deprivation on peripheral refractions and ocular shape in infant rhesus monkeys (*Macaca mulatta*). *Invest Ophthalmol Vis Sci*. 2009;50:4033-4044.
37. Smith EL 3rd, Huang J, Hung LF, Blasdel TL, Humbird TL, Bockhorst KH. Hemiretinal form deprivation: evidence for local control of eye growth and refractive development in infant monkeys. *Invest Ophthalmol Vis Sci*. 2009;50:5057-5069.
38. Nathan J, Kiely PM, Crewther SG, Crewther DP. Disease-associated visual image degradation and spherical refractive errors in children. *Am J Optom Physiol Opt*. 1985;62:680-688.
39. Sieving PA, Fishman GA. Refractive errors of retinitis pigmentosa patients. *Br J Ophthalmol*. 1978;62:163-167.
40. Knight-Nanan DM, O'Keefe M. Refractive outcome in eyes with retinopathy of prematurity treated with cryotherapy or diode laser: 3 year follow up. *Br J Ophthalmol*. 1996;80:998-1001.
41. Connolly BP, Ng EY, McNamara JA, Regillo CD, Vander JF, Tasman W. A comparison of laser photocoagulation with cryotherapy for threshold retinopathy of prematurity at 10 years: 2, refractive outcome. *Ophthalmology*. 2002;109:936-941.
42. Mutti DO, Sholtz RI, Friedman NE, Zadnik K. Peripheral refraction and ocular shape in children. *Invest Ophthalmol Vis Sci*. 2000;41:1022-1030.
43. Mutti DO, Hayes JR, Mitchell GL, et al. Refractive error, axial length, and relative peripheral refractive error before and after the onset of myopia. *Invest Ophthalmol Vis Sci*. 2007;48:2510-2519.
44. Wallman J, Winawer J. Homeostasis of eye growth and the question of myopia. *Neuron*. 2004;43:447-468.
45. Swarbrick HA, Wong G, O'Leary DJ. Corneal response to orthokeratology. *Optom Vis Sci*. 1998;75:791-799.
46. Charman WN, Mountford J, Atchison DA, Markwell EL. Peripheral refraction in orthokeratology patients. *Optom Vis Sci*. 2006;83:641-648.
47. Mathur A, Atchison DA. Effect of orthokeratology on peripheral aberrations of the eye. *Optom Vis Sci*. 2009;86:E476-E484.